

IC-8® SMALL APERTURE IOL

# Clinical Science Compendium

Summary of peer-reviewed clinical  
and bench research



**AcuFocus™**

# Introduction

Our mission at Acufocus is to deliver breakthrough, small-aperture intraocular products to address diverse unmet needs and help patients achieve their best personal vision.

In this compendium, you will find summaries of the peer-reviewed, published studies that guide our continuing development of the **IC-8**<sup>®</sup> small aperture IOL. This growing body of scientific evidence explains the method of action of the **IC-8** lens and demonstrates its ability to increase depth of focus and provide consistent management of residual refractive error including astigmatism.

We invite you to review these summaries to gain a deeper understanding of the science behind the **IC-8** small aperture IOL. In addition, please visit [www.acufocusuniversity.com](http://www.acufocusuniversity.com) for further information on the **IC-8** IOL.

## GLOSSARY OF TERMS

<b>CS</b> .....	Contrast Sensitivity	<b>PRK</b> .....	Photorefractive Keratectomy
<b>D</b> .....	Diopter	<b>RK</b> .....	Radial Keratotomy
<b>HOA</b> .....	Higher Order Aberration	<b>UDVA</b> .....	Uncorrected Distance Visual Acuity
<b>IOL</b> .....	Intraocular Lens	<b>UIVA</b> .....	Uncorrected Intermediate Visual Acuity
<b>LASIK</b> .....	Laser in Situ Keratomileusis	<b>UNVA</b> .....	Uncorrected Near Visual Acuity
<b>OD</b> .....	Right Eye	<b>CDVA</b> .....	Corrected Distance Visual Acuity
<b>OS</b> .....	Left Eye	<b>BCDVA</b> .....	Best-corrected Distance Visual Acuity
<b>OU</b> .....	Both Eyes		

# Table of Contents

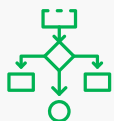
## IC-8® IOL METHOD OF ACTION & RESULTS IN NORMAL CORNEAS

<b>Prospective Multicenter Trial of a Small-Aperture Intraocular Lens in Cataract Surgery</b> .....	<b>04</b>
<i>Dick HB, Piovella M, Vukich J, Vilupuru S, Lin L. J Cataract Refract Surg 2017;43(7):956-968.</i>	
<b>The Small-Aperture IC-8 Intraocular Lens: A New Concept for Added Depth of Focus in Cataract Patients</b> .....	<b>06</b>
<i>Grabner G, Ang RE, Vilupuru S. Am J Ophthalmol. 2015 Dec;160(6):1176-1184.</i>	
<b>Small-Aperture Strategies for the Correction of Presbyopia</b> .....	<b>08</b>
<i>Dick HB. Curr Opin Ophthalmol 2019;30(4):236-242.</i>	
<b>A Comparative Evaluation of Visual Refractive and Patient-Reported Outcomes of EDOF Lenses</b> .....	<b>09</b>
<i>Ang RE, Picache GCS, Rivera MCR, Lopez LRL, Cruz EM. Clin Ophthalmol 2020;14:2339-2351.</i>	
<b>Visual Performance Comparison of 2 Extended Depth-of-Focus Intraocular Lenses</b> .....	<b>10</b>
<i>Schojai M, Schultz T, Jerke C, Böcker J, Dick HB. J Cataract Refract Surg 2020;46(3):388-393.</i>	
<b>Small-Aperture Intraocular Lens Tolerance to Induced Astigmatism</b> .....	<b>11</b>
<i>Ang RE. Clin Ophthalmol 2018;12:1659-1664.</i>	
<b>Comparison of Tolerance to Induced Astigmatism in Pseudophakic Eyes Implanted with Small Aperture, Trifocal, or Monofocal Intraocular Lenses</b> .....	<b>13</b>
<i>Ang RE. Clin Ophthalmol 2019;13:905-911.</i>	
<b>Binocular and Monocular Implantation of Small-Aperture Intraocular Lenses in Cataract Surgery</b> .....	<b>14</b>
<i>Dick HB, Elling M, Schultz T. J Refract Surg 2018;34(9):629-631</i>	
<b>Visual Performance of a Small-Aperture Intraocular Lens: First Comparison of Results after Contralateral and Bilateral Implantation</b> .....	<b>16</b>
<i>Ang RE. J Refract Surg 2020;36(1):12-19.</i>	
<b>Functional Outcomes and Reading Performance after Combined Implantation of a Small-Aperture Lens and a Segmental Refractive Bifocal Lens</b> .....	<b>17</b>
<i>Son HS, Khoramnia R, Yildirim TM, Baur I, Labuz G, Auffarth GU. J Refract Surg 2019;35(9):551-558.</i>	
<b>Posterior Segment Visualization in Eyes with Small-Aperture Intraocular Lenses</b> .....	<b>18</b>
<i>Srinivasan S, Khoo LW, Koshy Z. J Refract Surg 2019;35(8):538-542.</i>	

# Prospective Multicenter Trial of a Small-Aperture Intraocular Lens in Cataract Surgery

Dick HB, Piovella M, Vukich J, et al. J Cataract Refract Surg 2017;43:956-968

## OVERVIEW



### STUDY DESIGN

Prospective case series



### SUBJECTS & SITES

- 105 subjects
- 12 European clinics



### FOLLOW-UP

6 months



### KEY FEATURES

- Monocular implantation
- Normal corneas

## METHODOLOGY

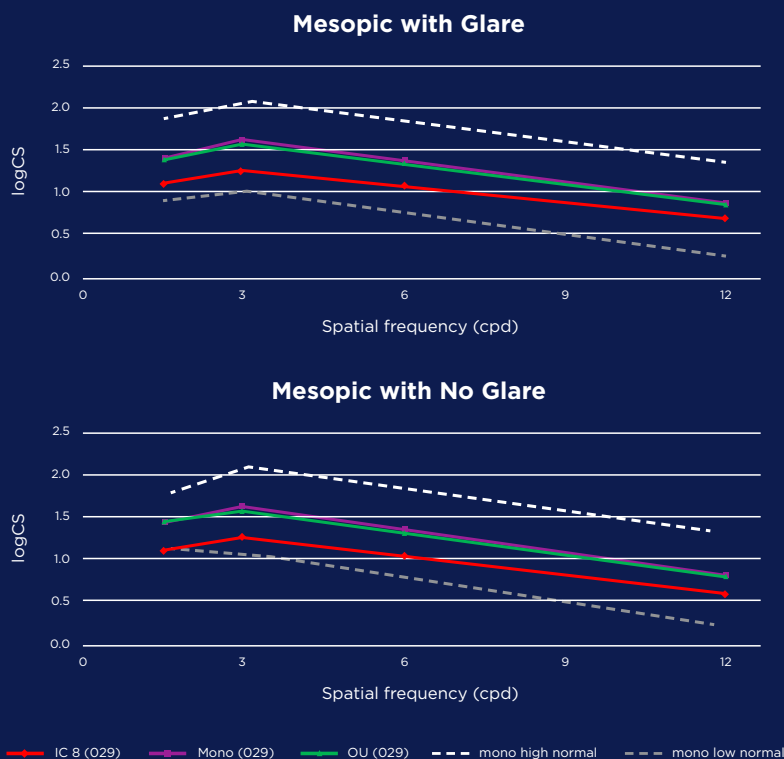
Visual performance was evaluated in subjects implanted with an **IC-8**<sup>®</sup> IOL in the nondominant eye (-0.75 D target) and an aspheric monofocal (plano target) in the fellow eye. Eyes with prior corneal or intraocular surgery, a pharmacologically dilated pupil smaller than 6.0 mm, retinal disorders, and corneal abnormalities were excluded. Preoperative corneal astigmatism  $\leq 1.75$  D was permitted, and results were analyzed according to the degree of preoperative cylinder.

## KEY FINDINGS

The data provide strong evidence that patients with the **IC-8** IOL maintain visual performance in eyes with as much as 1.5 D of corneal astigmatism. The mean uncorrected intermediate and near visual acuity (UIVA, UNVA) was 20/25 and 20/32, respectively, for up to 1.5 D of residual corneal astigmatism.

Mean uncorrected distance visual acuity (UDVA), UIVA, and UNVA in eyes with the **IC-8** IOL was 20/23, 20/24, and 20/30, respectively, compared to 20/21, 20/40, and 20/64, respectively, in fellow eyes with the monofocal IOL.

**Fig 1: Binocular contrast sensitivity, with (a) and without (b) glare for patients with contralateral IC-8 IOL and monofocal IOL implantation, is equivalent to the contrast sensitivity in the monofocal IOL eye.\***



\*European Post-Market Study on IC-8 IOL - Sub-Study at 6 months, n=36, Optec 6500. The low and high normal curves are defined as 1.96 SD from monofocal eye's CS curve.

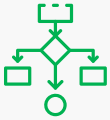
## ADDITIONAL RESULTS

- UDVA and UIVA remained unchanged between follow-up visits, while the UNVA improved by nearly 1 line from the 1-month to 6-month visits.
- The mean binocular defocus curves with distance correction showed a visual acuity of 0.2 logMAR (20/32) or better over a range of approximately 2.15 D of defocus. In a subset of 12 eyes, the mean binocular defocus curve with target correction (**IC-8** IOL eyes corrected to -0.75 D and monofocal IOL eyes corrected to plano) showed the same level of visual acuity over approximately 2.75 D. The **IC-8** IOL, when combined with a small amount of myopia (0.75 D), extended the range of functional near vision by 1.0 D without any loss to distance vision.
- At 6 months, 104 patients (99.0%), 100 patients (95.2%), and 83 patients (79.0%) achieved 20/32 or better binocular UDVA, UIVA, and UNVA, respectively.
- Most patients (95.9%) reported they would have the procedure again.
- Mesopic contrast sensitivity (CS) with and without glare was significantly better in the monofocal eyes compared to the **IC-8** IOL eyes (Fig 1). However, contrast sensitivity in the **IC-8** IOL eyes was still within normal limits for a monofocal IOL, and binocular CS mirrored the monofocal IOL CS performance.

# The Small-Aperture IC-8® Intraocular Lens: A New Concept for Added Depth of Focus in Cataract Patients

Grabner G, Ang RE, Vilupuru S. Am J Ophthalmol 2015;160(6):1176-1184

## OVERVIEW



### STUDY DESIGN

Prospective, non-comparative case series



### SUBJECTS & SITES

- 12 subjects
- 2 sites: Austria, Philippines



### FOLLOW-UP

12 months



### KEY FEATURES

- Pilot study
- Monocular implantation
- Normal corneas

## METHODOLOGY

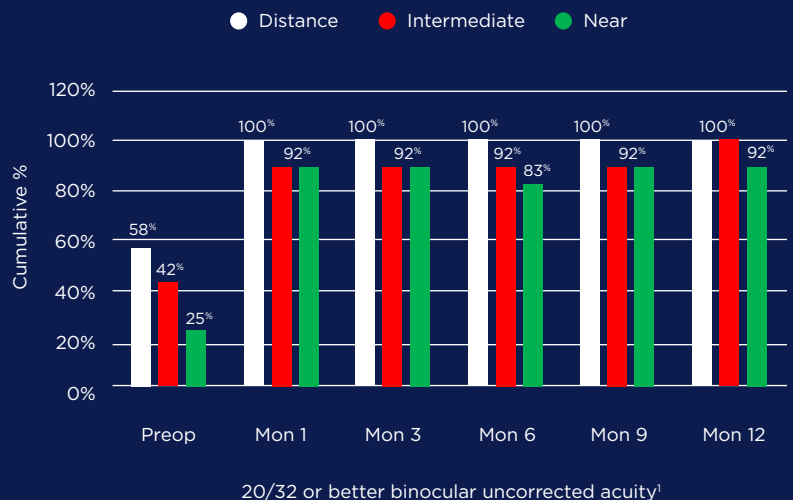
Uncorrected distance, intermediate, and near vision (UDVA, UIVA, and UNVA, respectively), as well as depth of focus and subjective symptoms, were measured in the first 12 patients implanted with the **IC-8** lens. Subjects had cataract but no other significant ocular pathology or prior surgery in the operative eye. This study was conducted prior to injector availability so the lenses were implanted flat through a 6.0-mm scleral incision. Implanted eyes were targeted for -0.75 D.

## KEY FINDINGS

At 12 months, mean monocular UNVA improved from J10 to J2 ( $P < .0001$ ); mean UIVA from 20/66 to 20/25 ( $P = 0.0002$ ), and mean UDVA from 20/50 to 20/20 ( $P < .0001$ ). All but 1 subject achieved 20/32 or better binocular visual acuity at all distances (Fig 1).

In 5 patients who underwent visual field testing and retinal evaluation with the **IC-8** lens in situ, a retinal surgeon was able to obtain fixation, locate the retinal structures, and acquire all needed scans, and was confident that laser treatment could be performed if needed.

Figure 1: Percentage of patients with 20/32 or better binocular UDVA, UIVA, and UCVA at all study timepoints in eyes implanted with the IC-8 IOL.



<sup>1</sup> Data on file. Acufocus, Inc

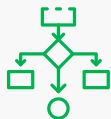
## ADDITIONAL RESULTS

- All eyes (100%) maintained 20/40 or better UDVA over a defocus range of +0.50 D to -1.50 D.
- Patient-reported satisfaction with near vision, on a scale of 1 to 7, improved from 2.9 preoperatively to 5.1 at 12 months. There were significantly lower complaints of blurry/fluctuating vision and glare at 12 months; there was no change in other visual symptoms.
- In the 5 patients who underwent visual field testing and retinal evaluation, mean VF deviation was  $-5.1 \pm 2.9$  and mean pattern standard deviation was  $1.4 \pm 2.2$  in the **IC-8** IOL eye.
- Although all eyes were targeted for -0.75 MRSE, the authors reported a greater tolerance for refractive misses because of the increased depth of focus with the **IC-8** IOL.

# Small-Aperture Strategies for the Correction of Presbyopia

Dick HB. Curr Opin Ophthalmol 2019;30(4):236-242.

## OVERVIEW



### STUDY DESIGN

Review



### SUBJECTS & SITES

N/A



### FOLLOW-UP

N/A



### KEY FEATURES

- Multi-platform review
- Monocular and binocular
- Normal and complex corneas

## METHODOLOGY

The field of small-aperture optics, which includes corneal inlays, contact lenses, IOLs, and topical pupil-constricting agents, is growing and changing rapidly. This article reviews what is known about the various platforms and discusses the impact of a small aperture on light perception and visual performance.

## KEY FINDINGS

Small-aperture optics are a dynamic, physiologic solution to the problem of presbyopia. In some forms, they may be able to reduce the impact of aberrations or improve vision in eyes with corneal irregularities, scars, or iris damage.

Perceived brightness through a small aperture is greater than what would be expected from theoretical calculations. This is likely due to a combination of binocular effects, the Stiles-Crawford effect, and neuroadaptation.

## ADDITIONAL FINDINGS

- Channeling light through a small aperture blocks incident stray light and unfocused peripheral light, minimizing the impact of corneal aberrations on vision.
- Numerous studies have now shown that while a small aperture causes some reduction in monocular contrast sensitivity (CS) under certain lighting conditions or spatial frequencies, there is minimal change in binocular CS.
- Monocular small-aperture surgery with a myopic target produces results that are quite different from monovision. A prospective study showed no significant change in stereoacuity 6 months after monocular inlay implantation.<sup>1</sup>
- Six months after implantation with a small-aperture IOL in one eye, 99%, 95%, and 79% of patients achieved 20/32 or better binocular UDVA, UIVA, and UNVA, respectively.<sup>2</sup>
- A contact lens is not the ideal platform for small aperture optics, as movement of the contact lens on the eye may not keep the aperture centered.
- A noninvasive topical approach has significant advantages. To be successful, it must be comfortable, well tolerated, have a long duration of effect, and be free from serious adverse events.

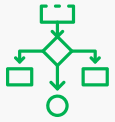
1. Linn S, Skanchy DF, Quist TS, et al. Stereoacuity after small aperture corneal inlay implantation. Clin Ophthalmol 2017; 11:233-235. 2. Dick HB, Piovella M, Vukich J, et al. Prospective multicenter trial of a small aperture intraocular lens in cataract surgery. J Cataract Refract Surg 2017; 43:956-968.



# A Comparative Evaluation of Visual, Refractive, and Patient-Reported Outcomes of Three Extended Depth of Focus (EDOF) Intraocular Lenses

Ang RE, Picache GCS, Rivera MCR, Lopez LRL, Cruz EM. Clin Ophthalmol 2020;14:2339-2351.

## OVERVIEW



### STUDY DESIGN

Retrospective cohort study



### SUBJECTS & SITES

- 94 eyes
- 1 site, Philippines



### FOLLOW-UP

3 - 63 months



### KEY FEATURES

- Normal corneas
- **IC-8**<sup>®</sup> IOL, Tecnis Symphony<sup>®</sup>, WIOL<sup>®</sup>

## METHODOLOGY

Subjects previously implanted with one of three extended depth of focus (EDOF) IOLs [Tecnis Symphony (n=32), **IC-8** IOL (n=30), and Mediem WIOL (n=32)] were recruited. Assessments included patient questionnaires, spherical equivalent, uncorrected and corrected visual acuity, defocus curve, modulation-transfer function (MTF), and visual Strehl optical transfer function (VSOTF) values.

## KEY FINDINGS

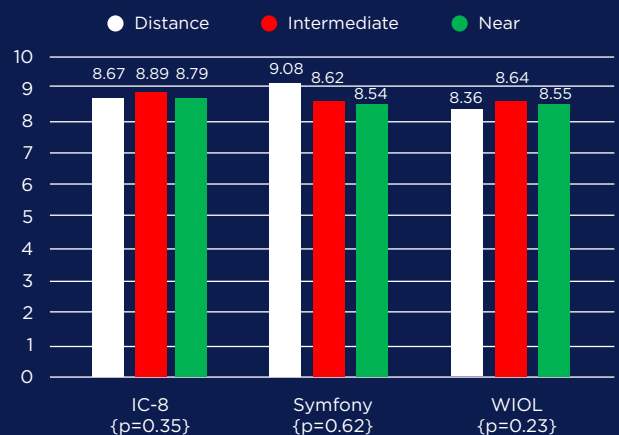
All eyes implanted with the three EDOF designs achieved excellent far and intermediate vision, with acceptable near vision. The **IC-8** IOL and Symphony IOL exhibited a better range of vision on defocus-curve testing. Patient satisfaction was high in all three EDOF groups (Fig 1). EDOF lenses elongate the focal range to provide better intermediate and near vision than monofocal lenses. Because they do not split light, they also address the shortcomings of multifocal IOLs, including photic phenomena and intermediate vision.

## ADDITIONAL FINDINGS

- In monocular defocus curve testing, the Symphony and **IC-8** IOLs had significantly better visual acuity, while the WIOL had poorer performance from manifest refraction up to 3.0 D of defocus. In binocular defocus testing, no significant difference was seen up to 2.5 D of defocus.
- There were no significant differences among the three groups for monocular or binocular glare, starbursts, or halos at night. When glare was noted in the Symphony and **IC-8** lens groups, it was only mild, with no impact on daily activities.
- Counter to expectations, contrast sensitivity scores were within normal limits for all three groups, with no statistical differences among the three groups in mesopic conditions, with or without, glare at 3, 6,

12, or 18 CPD. This suggests that the **IC-8** small aperture IOL transmits sufficient light for good photopic and mesopic vision.

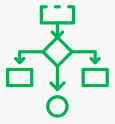
Figure 1: Patient Satisfaction Scores



# Visual Performance Comparison of 2 Extended Depth-of-Focus Intraocular Lenses

Schojai M, Schultz T, Jerke C, Böcker J, Dick HB. J Cataract Refract Surg 2020;46:388-393.

## OVERVIEW



### STUDY DESIGN

Prospective, randomized comparative trial



### SUBJECTS & SITES

- 38 subjects
- 1 site, Germany



### FOLLOW-UP

3 months



### KEY FEATURES

- Monocular implantation
- Normal corneas
- Comparator: TECNIS Symphony® IOL

## METHODOLOGY

Patients undergoing cataract surgery were randomized to be implanted with either bilateral Tecnis Symphony EDOF lenses or an **IC-8**® lens in the nondominant eye and a Tecnis® monofocal in the fellow eye. In both groups, the dominant eye was targeted for emmetropia and the nondominant eye for -0.75 D. Visual and refractive outcomes and patient satisfaction were evaluated.

## KEY FINDINGS

Uncorrected distance visual acuity (UDVA) was excellent in both groups with statistically better results in the **IC-8** lens group. Both groups had very good uncorrected intermediate and near vision, without significant differences (Fig 1).

Photoc phenomena were lower in the **IC-8** lens group, contributing to higher subjective patient satisfaction.

## ADDITIONAL FINDINGS

- UDVA was better in the **IC-8** lens group under photopic ( $0.1 \pm 0.07$  logMAR in the **IC-8** IOL group vs.  $0.07 \pm 0.1$  logMAR in the Symphony lens group,  $P=0.02$ ) and mesopic ( $0.12 \pm 0.09$  logMAR in the **IC-8** lens group vs.  $0.22 \pm 0.1$  logMAR in the Symphony lens group,  $P < .01$ ) conditions.
- Subjective overall patient satisfaction was high without spectacles or contact lenses in both groups. More patients in the Symphony group reported using spectacles throughout the day for distance objects, especially while driving.
- In the Symphony group, more patients reported halo, blurred vision, and changing visual acuity during the day than in the **IC-8** lens group. Symptoms of glare were reported in both groups.

Figure 1: Postoperative Uncorrected Near & Intermediate Visual Acuity Bilateral Symphony vs. IC-8/Monofocal Eyes

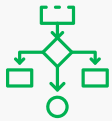
	Symphony Group	IC-8 Group
Binocular UIVA	$-0.01 \pm 0.08$	$0.01 \pm 0.07$
Monocular UIVA (nondominant eye)	$0.04 \pm 0.09$	$0.03 \pm 0.68$
Binocular UNVA	$0.09 \pm 0.08$	$0.14 \pm 0.11$
Monocular UNVA (nondominant eye)	$0.14 \pm 0.09$	$0.17 \pm 0.11$

UIVA at 67 cm; UNVA at 40 cm

# Small-Aperture Intraocular Lens Tolerance to Induced Astigmatism

Ang RE. Clin Ophthalmol 2018;12:1659-1664

## OVERVIEW



### STUDY DESIGN

Prospective observational pilot study



### SUBJECTS & SITES

- 10 subjects
- 1 site, Philippines



### FOLLOW-UP

N/A



### KEY FEATURES

- Monocular and binocular implantation
- Normal corneas

## METHODOLOGY

Eleven eyes of 10 subjects were implanted (9 unilaterally, 1 bilaterally) with an **IC-8**<sup>®</sup> small-aperture IOL. To be eligible, patients had to have best-corrected distance acuity (BCDVA) of 20/25 or better, clear intraocular media and no ocular pathology other than cataract. Baseline manifest refraction and BCDVA were measured with a Snellen Tumbling E chart. Astigmatic defocus was induced in the same axis as the manifest sphere-cylinder refraction or at 180° for a spherical refraction in 0.50 D steps up to -2.50 D, and distance visual acuity was measured at each level of defocus to determine the tolerance of the **IC-8** IOL to increasing levels of induced astigmatism.

## KEY FINDINGS

The **IC-8** IOL shows good tolerance to astigmatic defocus with 20/25 or better distance acuity maintained through 1.50 D cylinder.

Residual astigmatism after cataract surgery is a common source of patient dissatisfaction. The **IC-8** IOL approximately doubles the anticipated tolerance to astigmatism compared to multifocal IOLs.

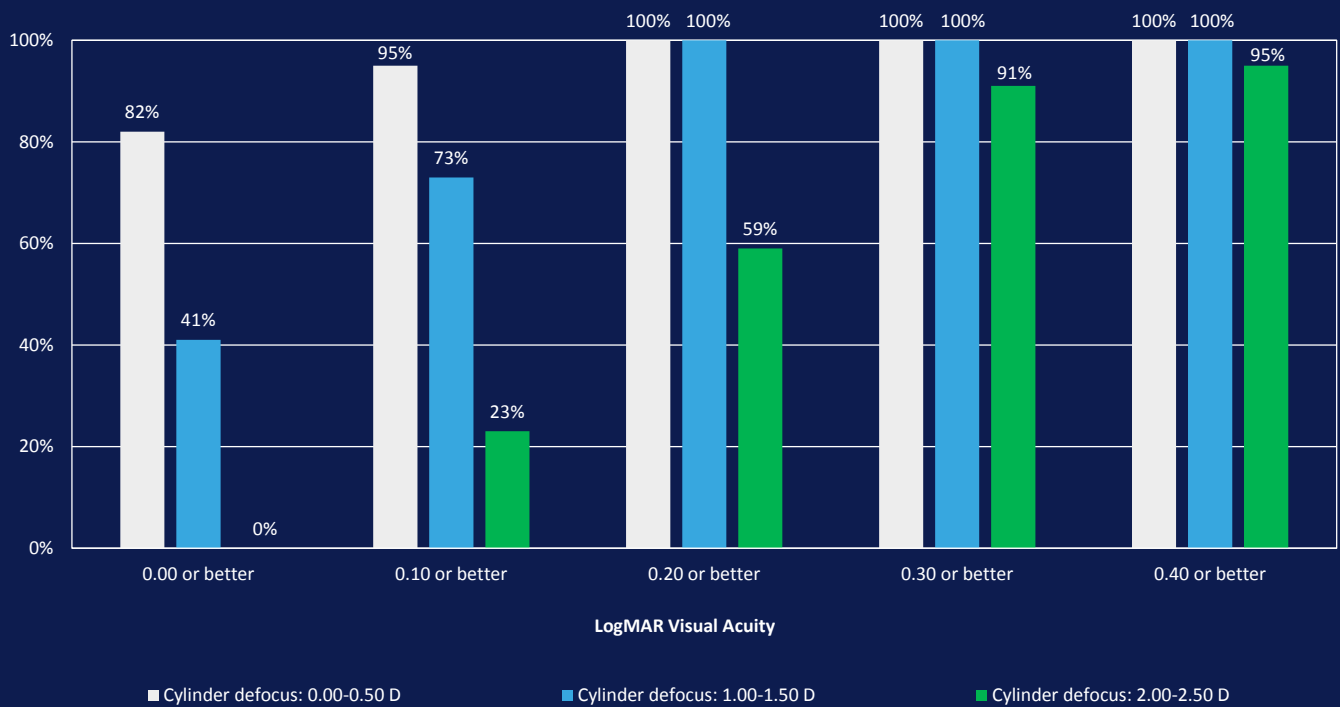
## ADDITIONAL FINDINGS

- The mean logMAR visual acuity showed a statistically significant difference from baseline at -1.00 D ( $P = 0.0025$ ), -1.50 D ( $P = 0.0009$ ), -2.00 D ( $P \leq 0.0001$ ), and -2.50 D ( $P \leq 0.0001$ ) of induced astigmatism.
- Mean distance visual acuity at each level of induced astigmatism defocus was as follows:
- Eight out of 10 subjects achieved 20/25 or better vision with 1.50 D of cylinder defocus, and all subjects were 20/30 or better. Ten out of 11 subjects were 20/40 or better with 2.50 D of defocus.
- Eyes with oblique or with-the-rule astigmatism showed slightly better maintenance of visual acuity at -1.00 and -1.50 D of induced cylinder defocus than eyes with against-the-rule astigmatism.

Defocus	mean $\pm$ SD (Snellen equivalent)
-0.50 D	0.02 $\pm$ 0.05 (20/21)
-1.00 D	0.07 $\pm$ 0.05 (20/24)
-1.50 D	0.08 $\pm$ 0.05 (20/24)
-2.00 D	0.19 $\pm$ 0.07 (20/31)
-2.50 D	0.26 $\pm$ 0.08 (20/36)

Continued on next page →

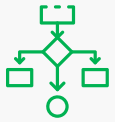
Fig. 1: Visual acuity in logMAR by cylinder defocus group



# Comparison of Tolerance to Induced Astigmatism in Pseudophakic Eyes Implanted with Small Aperture, Trifocal, or Monofocal Intraocular Lenses

Ang RE. Clin Ophthalmol 2019;13:905-911

## OVERVIEW



### STUDY DESIGN

Prospective comparative study



### SUBJECTS & SITES

- 44 subjects
- 1 site, Philippines



### FOLLOW-UP

N/A



### KEY FEATURES

- Monocular implantation
- **IC-8**<sup>®</sup> IOL, AT Lisa<sup>®</sup> IOL, FineVision<sup>®</sup> IOL, enVista<sup>®</sup> IOL
- Normal corneas

## METHODOLOGY

One eye of each patient was implanted with either an the **IC-8** IOL (n=12), FineVision IOL (n=9), AT Lisa IOL (n=10) or enVista IOL (n=13). Each patient's best-corrected manifest distance acuity was assessed, under increasing amounts of induced astigmatic defocus, using lenses in 0.5 D steps up to -2.5 D at three pre-determined axes (90°, 180°, and either 45° or 135°). Astigmatic tolerance was assessed as the difference between logMAR visual acuity at 0.0 D and each defocus step.

## KEY FINDINGS

Across all three axes, the small aperture **IC-8** IOL showed greater tolerance to induced astigmatic defocus than trifocal and monofocal IOLs (Fig 1). The **IC-8** IOL group maintained good visual acuity with no more than one line of loss from baseline with up to 1.4 D of induced astigmatism.

## ADDITIONAL FINDINGS

- The astigmatic tolerance in the **IC-8** lens group was significantly better than the AT Lisa group for 0.5 D to 2.5 D of defocus and the FineVision group for 0.5 D to 1.5 D of defocus (all  $P < 0.05$ , ANOVA). The difference in astigmatic tolerance between the **IC-8** lens and the enVista lens was not statistically significant ( $P > 0.05$ , ANOVA).
- The largest differences in astigmatic defocus range between **IC-8** IOL and trifocal eyes were in the oblique axes (1.4 D for the **IC-8** lens group vs. 0.5 D and 0.4 D for the FineVision and AT Lisa groups, respectively).
- The small aperture design of the **IC-8** IOL improves astigmatic tolerance by blocking aberrated peripheral light rays, effectively decreasing the size of the blur circle.

- About one-third of cataract patients have astigmatism outside the range of tolerance of multifocal IOLs, but within the tolerance range of the **IC-8** IOL.
- Awareness of astigmatic tolerance is important for surgical planning, to maximize patient satisfaction and avoid the need for secondary astigmatism management

### Fig. 1: Astigmatic Tolerance (d)

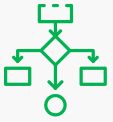
(Mean astigmatic defocus resulting in loss of 1 line of visual acuity compared to 0.00 D defocus)

Axis	iC-8	Fine Vision	AT Lisa	enVista
90°	1.5	0.7	1.1	1.1
180°	1.2	0.8	0.8	1.1
Oblique (45° or 135°)	1.4	0.5	0.4	1.0
<b>All axes combined</b>	<b>1.4</b>	<b>0.7</b>	<b>0.7</b>	<b>1.0</b>

# Binocular and Monocular Implantation of Small-Aperture Intraocular Lenses in Cataract Surgery

Dick HB, Elling M, Schultz T. J Refract Surg 2018;34(9):629-631

## OVERVIEW



### STUDY DESIGN

Comparative case series



### SUBJECTS & SITES

- 17 subjects
- 1 site, Germany



### FOLLOW-UP

6 months



### KEY FEATURES

- Monocular vs binocular implantation
- Normal corneas

## METHODOLOGY

Postoperative visual outcomes, defocus curve, patient satisfaction, and visual symptoms at 1, 3, and 6 months were compared between 11 patients who underwent cataract surgery with monocular implantation of the **IC-8**<sup>®</sup> IOL (Contralateral group) and 6 patients who underwent binocular **IC-8** IOL implantation (Bilateral group). The refractive target was -0.50 to -0.75 D in the **IC-8** IOL eyes in the Contralateral Group and in the nondominant eyes of the Bilateral Group. The dominant eyes in the Bilateral Group had a plano target.

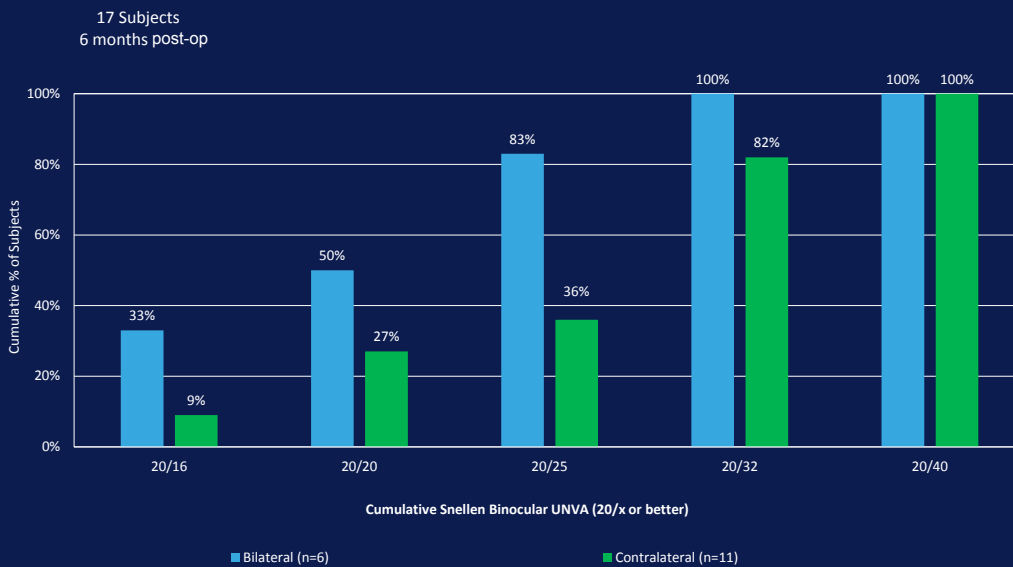
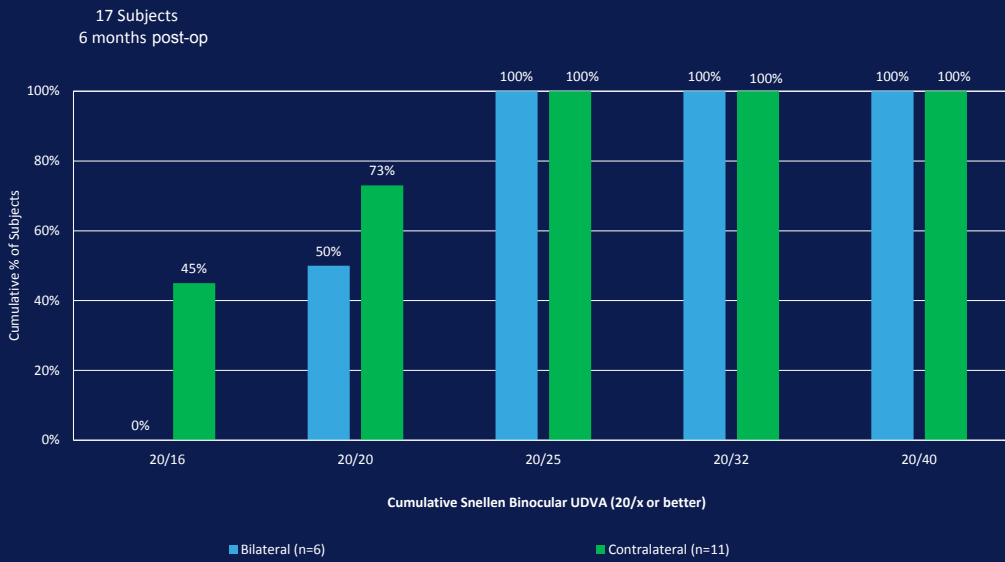
## KEY FINDINGS

Bilateral implantation of the **IC-8** IOL resulted in an extended range of focus, with better intermediate and near vision for the Bilateral Group versus the Contralateral Group. Monocular implantation of the **IC-8** IOL resulted in a significantly higher overall satisfaction score ( $4.5 \pm 0.7$  vs.  $3.0 \pm 1.7$ ,  $p=0.48$ ) and lower halo severity score ( $0.5 \pm 1.2$  vs.  $3.7 \pm 0.5$ ,  $p=0.001$ ) for the Contralateral Group versus the Bilateral Group.

## ADDITIONAL FINDINGS

- Significantly better binocular UIVA ( $P = .029$ ), UNVA ( $P = .049$ ), DCIVA ( $P = .043$ ), and DCNVA ( $P = .038$ ) were found in the Bilateral Group compared to the Contralateral Group at 3 months after surgery. The same trend but without significance was observed at 6 months after surgery for near visual acuities ( $P \geq .143$ ).
- Lower patient satisfaction with distance and intermediate vision was reported in the Bilateral Group, but the differences did not reach statistical significance ( $P \geq .068$ ). All patients in the Contralateral Group indicated they would undergo the surgery again, compared to 83% of patients in the Bilateral Group ( $P = .205$ ).
- The defocus curve revealed higher visual acuity at negative defocus levels in the Bilateral Group. However, both curves showed the same peak (0.00 D logMAR).
- The level of near visual acuity achieved with **IC-8** IOLs implanted in both eyes was comparable to that reported with various multifocal IOLs.
- The authors discuss the difference in satisfaction scores and visual effects as potentially related to significant differences in pupil size between the two groups with the Bilateral Group presenting with a larger preoperative pupil size than the Contralateral Group.

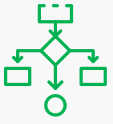
Fig. 1: Binocular uncorrected visual acuity at distance (A) and near (B) 6 months after surgery



# Visual Performance of a Small-Aperture Intraocular Lens: First Comparison of Results after Contralateral and Bilateral Implantation

Ang RE. J Refract Surg 2020;36(1):12-19.

## OVERVIEW



### STUDY DESIGN

Prospective, non-randomized study



### SUBJECTS & SITES

- 10 subjects
- 1 site, Philippines



### FOLLOW-UP

12 months



### KEY FEATURES

- Monocular implantation
- Normal corneas

## METHODOLOGY

Ten contralateral patients were implanted with a monofocal IOL in one eye and an **IC-8**<sup>®</sup> IOL in the other (contralateral group). Another 10 patients were implanted with an **IC-8** IOL in both eyes (bilateral group). Visual acuity, patient satisfaction, ease of task performance, visual symptoms, defocus curves, and contrast sensitivity were evaluated in both groups.

## KEY FINDINGS

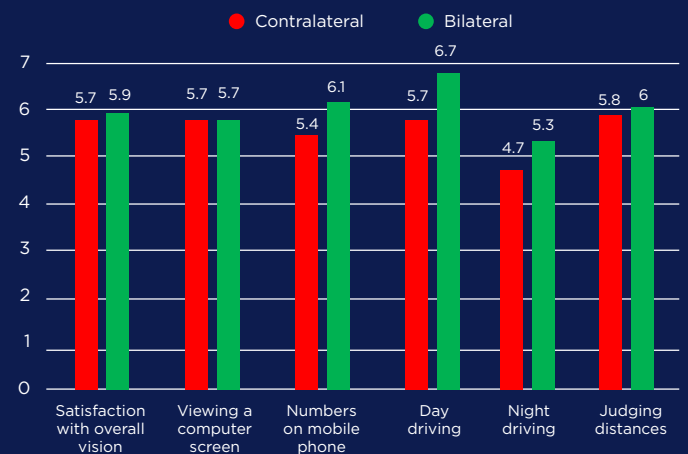
Bilateral implantation of the **IC-8** IOL extended the depth focus range by 0.25 D and improved binocular uncorrected intermediate and uncorrected near visual acuity by 0.5 to 1 line compared to the contralateral patients. Bilateral patients had better overall satisfaction, satisfaction with near tasks, and spectacle independence than contralateral patients and they rated many near tasks as easier to perform.

## ADDITIONAL FINDINGS

- All 10 (100%) contralateral and 10 (100%) bilateral patients achieved 20/32 or better binocular uncorrected and corrected distance visual acuity at all distances.
- All distance-corrected visual acuities remained stable over 12 months postoperatively ( $P > .05$ ).
- Mean contrast sensitivity was similar in both groups for mesopic conditions with or without glare at all spatial frequencies ( $P > .05$ ).
- Bilateral implantation requires careful patient selection and optimization of refractive targets. In the bilateral group, the first eye was targeted for myopia (-0.50 to -0.75 D) and the second eye for emmetropia. If desired near or intermediate outcomes were not achieved in the first eye, then the second eye was targeted for more myopia.

- No statistically significant differences were detected in patient-reported symptoms between the contralateral and bilateral groups ( $P > .05$ ). No correlations were found between pupil size, patient satisfaction, and visual symptoms.

Figure 1: Patient-Reported Satisfaction Scores (Scale 1-7, with 7=best)

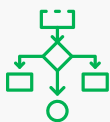




# Functional Outcomes and Reading Performance after Combined Implantation of a Small-Aperture Lens and a Segmental Refractive Bifocal Lens

Son H-S, Khoramnia R, Yildirim TM, Baur I, Labuz G, Auffarth GU. J Refract Surg 2019;35(9):551-558.

## OVERVIEW



### STUDY DESIGN

Prospective study



### SUBJECTS & SITES

- 13 subjects
- 1 site, Germany



### FOLLOW-UP

5 months



### KEY FEATURES

- Monocular implantation
- Normal corneas
- Paired with Lentis® Mplus LS-313 MF20 IOL

## METHODOLOGY

Subjects undergoing standard bilateral cataract surgery were implanted with the **IC-8**® IOL in the nondominant eye and a segmented low-add bifocal IOL (Lentis Mplus LS-313 MF20 IOL, Oculentis) in the fellow eye. The **IC-8** IOL eyes were targeted for -0.5 D, while the Mplus eyes were targeted for emmetropia. In addition to visual acuity and defocus curve measurements, a Salzburg Reading Desk was used to assess reading acuity 5 months postoperatively. A halo and glare simulator was used to evaluate postoperative dysphotopsia.

## KEY FINDINGS

Patients with this combination of IOLs experienced excellent visual performance at distance and intermediate and functional visual acuity at near, with minimal photic phenomena. Reading speeds > 80 wpm suggested patients' ability to comfortably perform daily intermediate and near tasks. (Fig 1)

## ADDITIONAL FINDINGS

- This is the first study to report clinical outcomes after mix-and-match implantation of **IC-8** and Mplus IOLs.
- Both IOLs resulted in statistically significant improvements in corrected distance visual acuity (CDVA) after surgery compared to preoperative CDVA.
- At 5 months postoperatively, the mean binocular visual results demonstrated UDVA (4 m), UIVA (80 cm), and UNVA (40 cm) values of  $-0.04 \pm 0.11$ ,  $0.00 \pm 0.10$ , and  $0.11 \pm 0.08$  logMAR, respectively.
- Subjects achieved distance-corrected binocular reading acuity of 0.11 logMAR at a fixed distance of 78.03 cm and 0.12 logMAR at a subjectively preferred distance of 69.21 cm.
- Two patients reported not perceiving any halo at all and 9 patients reported not perceiving any glare. The mean halo size was  $32.54 \pm 22.38$  (range: 0 to 68) and mean halo intensity was  $34.46 \pm 21.95$  (range: 0 to 79).

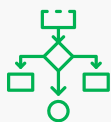
Figure 1: Binocular Intermediate & Near Reading Performance with Salzburg Reading Desk

	Intermediate at 80cm	Preferred Intermediate (mean 61.9 ± 6.41 cm)	P value	Near at 40 cm	Preferred Near (Mean 41.63 ± 5.94 cm)	P value
Reading Acuity (logMAR) Mean (range)	0.11 (0.00-0.22)	0.12 (0.01-0.22)	0.7795	0.21 (0.00-0.41)	0.19 (0.08-0.37)	0.7949
Reading Speed (wpm) Mean (range)	115.23 (84-219)	119.46 (81-206)	0.7795	138.00 (88-424)	118.00 (80-200)	0.7566

# Posterior Segment Visualization in Eyes with Small-Aperture Intraocular Lens

Srinivasan S, Khoo LW, Koshy Z. J Refract Surg 2019;35(8):538-542.

## OVERVIEW



### STUDY DESIGN

Prospective comparative case series



### SUBJECTS & SITES

- 15 subjects
- 1 site, Scotland



### FOLLOW-UP

2 months



### KEY FEATURES

- Monocular implantation
- Normal corneas

## METHODOLOGY

In this fellow-eye comparative study, 15 patients underwent cataract surgery with an **IC-8**<sup>®</sup> IOL in the nondominant eye and a colorless monofocal IOL (n=14) or no cataract surgery (n=1) in the dominant eye. Two months after surgery, standard posterior segment examinations were performed bilaterally, under scotopic conditions and without topical mydriatic agents. An independent ophthalmologist who was masked to the laterality and type of IOL evaluated the digital retinal images and scored them from 0 (worst) to 4 (best).

## KEY FINDINGS

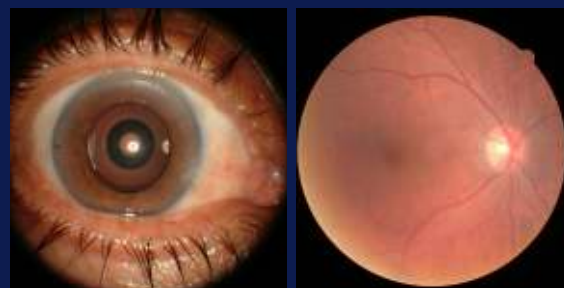
All elements of the posterior segment exam, including fundus imaging, 24-2 threshold automated perimetry, and optical coherence tomography (OCT), were successfully performed in all eyes.

An experienced, masked retinal surgeon could not detect any differences in image quality between the eyes implanted with standard monofocal IOLs and those with small-aperture IOLs. All images were graded as a 4 (i.e., clear view, able to clearly view and interpret the test results).

## ADDITIONAL FINDINGS

- One subject developed postoperative endophthalmitis. Using a non-contact fundus viewing system, the retinal surgeon was able to visualize the posterior pole and the peripheral retina through the **IC-8** IOL.
- The retinal surgeon was also able to perform all needed maneuvers, including a complete posterior vitrectomy, posterior vitreous detachment, shaving the vitreous base, and examining the peripheral retina for entry site tears.
- This initial case series did not address how the intraoperative view would be affected in other vitreoretinal procedures, such as membrane peeling.

**Figure 1: Fundus photography with a non-mydriatic fundus camera and macular OCT postoperatively.**



Photos courtesy: Dr. Gabriel Quesada

AcuFocus, Inc.

32 Discovery, Suite 200, Irvine, CA 92618 | +1 949.585.9511 | [www.acufocus.com](http://www.acufocus.com)

© 2021. AcuFocus, Inc. All rights reserved. AcuFocus, The Small Aperture Company, IC-8, and the IC-8 logo are trademarks or registered trademarks of AcuFocus, Inc.

ED-912 Rev A

